

Reovirus Replication in Ovarian and Peritoneal Tumors After Intravenous Administration

Mitch A. Phelps¹, David E. Cohn¹, David M. O'Malley¹, Lai Wei¹, Deidre Wilkins¹, Angela Campbell¹, Larry J. Schaaf¹, Matthew C. Coffey², Miguel A. Villalona-Calero¹, Michael R. Grever¹, James A. Zwiebel³, Gerard J. Nuovo¹

¹The Ohio State University, Columbus, OH; ²Oncolytics Biotech, Inc., Calgary, AB, Canada; ³National Cancer Institute, Bethesda, MD

ABSTRACT

Background: Reovirus Serotype 3 - Dearing Strain is an oncolytic virus under clinical evaluation for treatment of solid tumor malignancies. We initiated a phase 1/2 study with reovirus in patients with ovarian, primary peritoneal and fallopian tube carcinoma. The objectives of the correlative studies in this trial include the verification of reovirus penetration and replication in ovarian and peritoneal tumors after IV and IP administration and to evaluate tumor RAS pathway activation status as a marker for reovirus activity in this patient population.

Methods: Percutaneous tumor biopsies and ascites fluid were collected at various times during therapy from patients receiving reovirus via both IV and IP routes. Biopsied tissue and cell preparations from ascites were evaluated for viral protein via immunohistochemistry (IHC). Additional staining was conducted to evaluate reovirus colocalization with microtubules as evidence of intracellular viral replication.

Results: As of April 1, 2010, 7 patients have been accrued and treated on trial. Evaluation with IHC indicates the presence of viral protein in the biopsied ovarian and peritoneal tissue samples from a subset of these patients after IV administration of reovirus. Furthermore, IHC indicates increased virus signal in tumor compared to normal cells and evidence of colocalized viral protein and microtubules.

Conclusions: Results to date display evidence of viral replication in peritoneal and ovarian cancer cells after IV administration. This data represents the first observation of reovirus penetration into the peritoneal space after systemic drug administration. Immunostaining indicating overlap of viral protein and microtubule signals may be evidence of active reovirus replication in tumor cells. Work continues to further confirm these findings and to evaluate the role of RAS and PKR activity in reovirus infection and replication.

STUDY OBJECTIVES

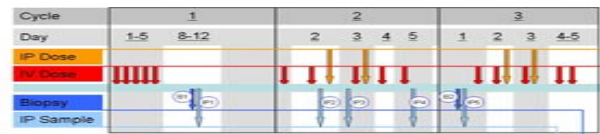
1. To determine the safety and tolerability of IV and IP reovirus in patients with recurrent, platinum-refractory ovarian, peritoneal and tubal carcinomas.
2. To determine the maximum tolerated dose of IP reovirus when used with a fixed dose of IV reovirus
3. To identify viral replication in tumor biopsies and ascites samples following IV and IP reovirus
4. To correlate viral replication and response to therapy with Ras and PKR activity in tumors

METHODS AND RESULTS

Reovirus administration and accrual:

A. Trial Design: Patients were treated on 28 day cycles with fixed IV dosing of reovirus (3×10^{10} TCID₅₀/day) days 1-5 and IP dosing on days 2 and 3 (IP dosing begins Cycle 2 for the phase 1 study). The phase 1 portion of this study includes inter-patient dose escalation of the IP dose only.

B. Patient Accrual and Treatment: To date, 7 patients have been enrolled and treated on study. IP dose escalation is currently at level 2 (3×10^9 TCID₅₀/day) in the phase 1 study. No DLTs have been observed to date. Samples are collected as indicated in scheme 1 below.



Scheme 1: Dosing and Biopsy/Ascites Sampling.

Reovirus tissue sampling occurs during cycles 1-3. A maximum of 2 CT-guided percutaneous tumor biopsies and 5 intraperitoneal washings (ascites) are collected from each patient at various times after IV and IP dosing to evaluate viral infection and replication.

Immunohistochemistry:

Tumor biopsy and ascites samples obtained at various times after IV and IP reovirus dosing were formalin fixed and paraffin embedded, and 4 μm sections were mounted on slides. Immunohistochemical analysis of reovirus protein was completed with a goat primary antibody to reovirus capsid protein (dilution 1:6000) and rabbit anti-goat secondary (1:500). The Benchmark LT automated system (Ventana Medical Systems, Tucson, AZ) was used to optimize conditions from blinded analysis of cells either infected or not with reovirus using diluted primary and secondary antibodies following pretreatment in Ventana's cell conditioning solution CC1 for 30 minutes (antigen retrieval). The antigen was detected with the Ultraview Universal DAB or Fast Red system from Ventana with a counterstain of hematoxylin. Negative controls included carcinomas from patients not dosed with reovirus and omission of primary antibody. The Nuance System (Cambridge Research Institute) was used for colocalization of reovirus and microtubules. Optimized conditions included protease digestion with protease 1 (Ventana) for 4 minutes and a 1:5 dilution with the mouse primary Microtubules antibody [AE-8] (Abcam).

CONCLUSIONS

1. Evidence of viral capsid protein in tumor tissue after IV administration indicates penetration of reovirus into peritoneal tumors after systemic administration.
2. Comparison of viral protein load in tumor vs. normal cells indicates a selective infection and/or replication in tumor cells.
3. Overlap of viral protein and microtubule signals suggests reovirus replication occurs within tumor cells.

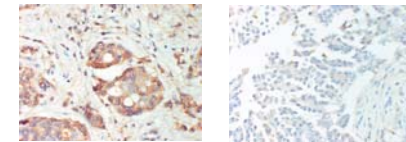


Figure 1: Immunohistochemistry of reovirus in peritoneal tumors. Representative IHC staining of formalin fixed, paraffin embedded tissue sections from CT-guided biopsies from patients with peritoneal tumors after IV reovirus administration. Reovirus is indicated with brown staining of tumor cells in one patient (left) but is absent the other (right). Positive staining is localized primarily to tumor cells with minimal signal in surrounding normal cells.

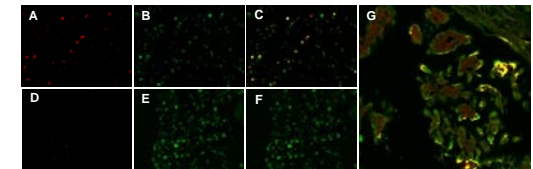


Figure 2: Co-detection of reovirus and microtubulin proteins. Cell lines infected (A-C) or not (D-F) with reovirus were used to optimize conditions for detection of viral protein (red) and microtubules (green). Overlap (C,F) of reovirus signal (A,D) with microtubule signal (B,E) indicates colocalization of the two (yellow) in reovirus infected cells (C). Panel G displays representative staining and colocalization of reovirus and microtubules from a peritoneal tumor biopsy section from a patient who had received IV reovirus.

ACKNOWLEDGEMENTS

Thanks to Kathleen Sergott and Ventana Medical Systems for providing reagents used in IHC analysis. This work was supported by the NCI, grant U01CA076576 (to MRG) and contract N01CM62207 (to MAV)